

Redo of sympathetic renal denervation in a patient with resistant hypertension and anatomical variation of renal arteries

Karol Kasprzycki¹, Agata Krawczyk-Ożóg^{1,2}, Łukasz Rzeszutko^{1,3}, Stanisław Bartuś^{1,3}, Renata Rajtar-Salwa¹

¹Clinical Department of Cardiology and Cardiovascular Interventions, University Hospital, Krakow, Poland

²Department of Anatomy, Jagiellonian University Medical College, Krakow, Poland

³2nd Department of Cardiology, Institute of Cardiology, Jagiellonian University Medical College, Krakow, Poland

Adv Interv Cardiol 2023; 19, 2 (72): 190–191
DOI: <https://doi.org/10.5114/aic.2023.129220>

A 46-year-old woman with resistant hypertension, chronic heart failure, hyperlipidemia, obesity (body mass index (BMI) 30 kg/m²), and hypertensive retinopathy was admitted for percutaneous renal artery denervation (RDN). She experienced severe headaches (10/10 on the NRS scale) and visual disturbances. Five months before admission, central retinal artery occlusion of the left eye occurred. 24-hour ambulatory blood pressure monitoring (ABPM) revealed increased blood pressure (mean value: 191/125 mm Hg; during day 195/130 mm Hg; during night 186/121 mm Hg, non-dipper circadian rhythm) despite using pharmacotherapy with nine antihypertensive drugs: telmisartan (2 × 40 mg), bisoprolol (1 × 5 mg), amlodipine (2 × 10 mg), spironolactone (1 × 25 mg), torasemide (1 × 5 mg), indapamide (1 × 1.5 mg), doxazosin (1 × 4 mg), clonidine (3 × 225 µg), methyl dopa (3 × 250 mg). Secondary hypertension causes were excluded. Moreover, she had no symptoms of obstructive sleep apnea.

RDN was performed using the Symplicity Spyral multi-electrode catheter (Medtronic, Minneapolis, MN, USA). Ten ablations of the left renal artery and fourteen ablations of the right renal artery were conducted (Figures 1 A, B). The procedure was uneventful. Post-procedure ABPM showed significant blood pressure reduction (mean value: 146/73 mm Hg, during the day 150/77 mm Hg, during the night 144/70). The patient was discharged with eight antihypertensive drugs: telmisartan (2 × 40 mg), bisoprolol (1 × 5 mg), amlodipine (1 × 10 mg), spironolactone (1 × 25 mg), torasemide (1 × 5 mg), indapamide (1 × 1.5 mg), doxazosin (1 × 4 mg), clonidine (3 × 225 µg).

Two months later, severe headaches returned, and ABPM revealed high blood pressure (mean value: 188/124 mm Hg, during the day 192/130 mm Hg; during the night 185/119 mm Hg). Hypertension therapy was modi-

fied: lisinopril (2 × 40 mg), bisoprolol (1 × 5 mg), amlodipine (1 × 10 mg), spironolactone (1 × 50 mg), torasemide (1 × 5 mg), indapamide (1 × 1.5 mg), doxazosin (1 × 8 mg), clonidine (3 × 225 µg). Due to the persistence of the symptoms and the initial significant decrease in blood pressure after RDN, a repeat procedure was indicated. The RDN procedure was performed using the Symplicity Spyral multi-electrode catheter. Eighteen ablations in the left renal artery and sixteen ablations in the right renal artery were performed during the second procedure (Figure 1 C). Blood pressure decreased significantly (ABPM mean value: 146/78 mm Hg, during the day 147/77 mm Hg; during the night 143/79 mm Hg). The patient was discharged with seven antihypertensive drugs: lisinopril (2 × 40 mg), bisoprolol (1 × 5 mg), amlodipine (1 × 10 mg), spironolactone (1 × 50 mg), torasemide (1 × 10 mg), indapamide (1 × 1.5 mg), doxazosin (1 × 8 mg).

Follow-up visits revealed high blood pressure values again. ABPM performed after one month showed a mean daily blood pressure value of 191/108 mm Hg (during the day 199/114 mm Hg; during night 170/92 mm Hg) and after 6 months: 210/106 mm Hg (during the day 220/112 mm Hg; during night 189/96 mm Hg).

According to the European Society of Cardiology and the European Society of Hypertension (ESC/ESH) guidelines, RDN is not routinely recommended but can be performed in specialized centers in patients in whom multi-drug pharmacotherapy of hypertension is ineffective [1, 2].

Accessory renal arteries or early branches of the renal arteries and their incomplete denervation are associated with a lower RDN response rate. Additionally, patients with resistant hypertension have a higher prevalence of accessory renal arteries. Our patient did not have the early polar branch of the renal artery ablated due to its

Corresponding author:

Karol Kasprzycki, Department of Cardiology and Cardiovascular Interventions, University Hospital, 2 Jakubowskiego St, 30-688 Kraków, Poland, e-mail: kasprzyckikarol@gmail.com

Received: 12.04.2023, accepted: 14.05.2023.

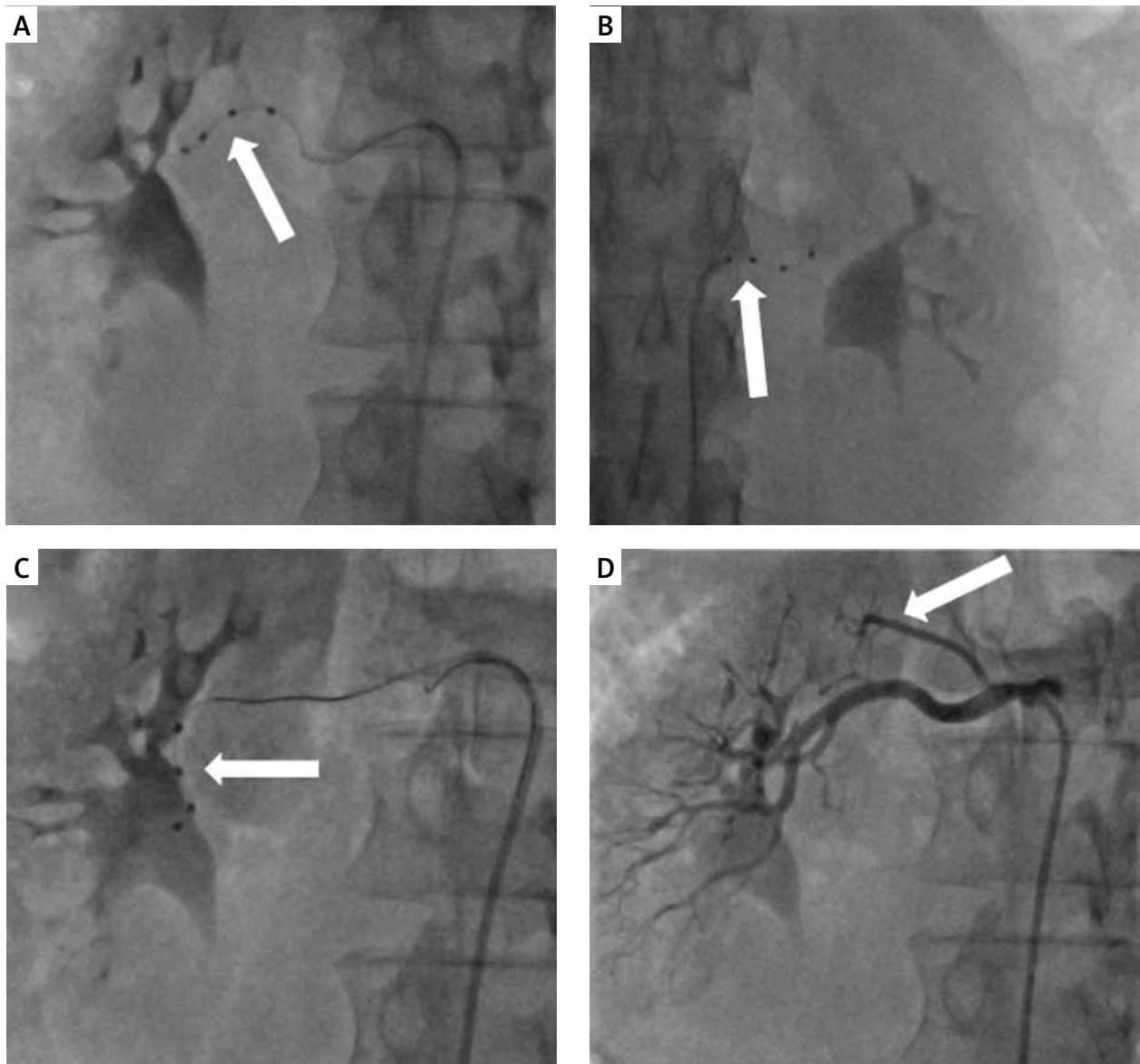


Figure 1. **A, B** – Initial renal artery denervation procedure (2020) using the Symplicity Spyral catheter in the right and left renal arteries (white arrows). **C** – Repeat renal artery denervation procedure (2021) using the Symplicity Spyral catheter in the right renal artery (white arrow). **D** – Right renal artery angiography showing the early polar branch of the right renal artery (white arrow)

small diameter (Figure 1 D). Most of the clinical trials performed so far have not performed ablation in vessels < 4 mm in diameter [3, 4]. Precise patient selection appears crucial for improving RDN effectiveness [5].

Conflict of interest

The authors declare no conflict of interest.

References

1. Williams B, Mancia G, Spiering W, et al. 2018 ESC/ESH Guidelines for the management of arterial hypertension. *Eur Heart J* 2018; 39: 3021-104.
2. Tokarek T, Rajtar-Salwa R, Rzeszutko Ł, Bartuś S. Long-term benefit of redo sympathetic renal denervation in a patient with resistant hypertension. *Adv Interv Cardiol* 2021; 17: 239-41.
3. VonAchen P, Hamann J, Houghland T, et al. Accessory renal arteries: prevalence in resistant hypertension and an important role in nonresponse to radiofrequency renal denervation. *Cardiovasc Revasc Med* 2016; 17: 470-3.
4. Id D, Kaltenbach B, Bertog SC, et al. Does the presence of accessory renal arteries affect the efficacy of renal denervation? *JACC Cardiovasc Interv* 2013; 6: 1085-91.
5. Li S, Phillips JK. Patient selection for renal denervation in hypertensive patients: what makes a good candidate? *Vasc Health Risk Manag* 2022; 18: 375-86.